



**Implant Dentistry @ HKU**  
 Education

**Maintaining Long-term Success with Dental Implants:**  
 Prevention and management of complications!






**Nikos Mattheos**  
 The University of Hong Kong

**Faculty of Dentistry**  
 The University of Hong Kong  
 CENTER FOR ADVANCED DENTISTRY  
 牙醫學院 牙醫高級研究中心



**馬毅剛**

2 yrs part time MSc in Implant Dentistry  
 3 yrs full time MDS in Implant Dentistry  
 patient care, research.





Brånemark/Zarb/Albrektsson  
**Tissue-Integrated Protheses**  
 Osseointegration in Clinical Dentistry

with contributions by:  
 Ragnar Axel, Sig Blomberg,  
 Gunnar E. Carlsson,  
 Per-Olof Glantz, Turgay Haralsson,  
 Thomas Jansson, Torsten Jemt,  
 Bengt Kvarnemo, Jukka Levenstam,  
 Ulf Lekholm, Richard Skalak,  
 Karl-Gösta Thoms,  
 A. H. Ten Cate,  
 Anders Thilander





**1975**



**Super Specialist**

General Practitioner →  
 Predictable  
 Safe  
 Successful

**2019**



**Success**

**Predictable**

**Sustainable**



Swedish Dental Journal, Supplement 213, 2011

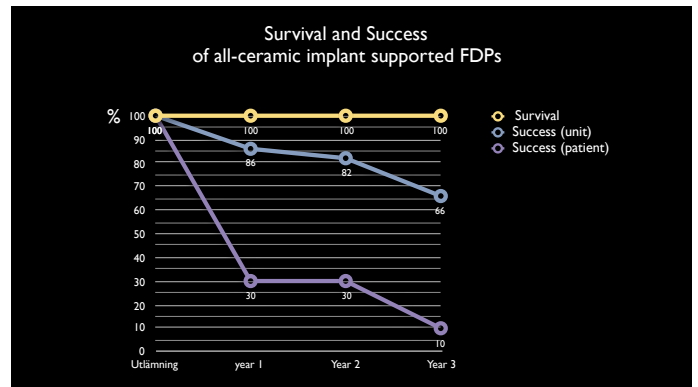
**CHRISTEL LARSSON**  
**ZIRCONIUM DIOXIDE BASED DENTAL RESTORATIONS**  
Studies on clinical performance and fracture behaviour






**Zirkoniumdioxid-baserade rekonstruktioner fungerar**

... men designen är viktig för hållbarheten




**Osseointegration**  
2,785 Pat. 11,311 Imp



✓ 4.4 %    ✓ 1.4 %

**9 years**  
596 Pat. 2367 Imp



✓ 95.8 %    ✓ 98 %  
✓ 14.5 %    ✓ 8 %

moderate / severe peri implantitis


J. Derks, J. Håkansson, J.L. Wennström, C. Tomasi, M. Larsson, T. Berglundh. Effectiveness of Implant Therapy Analyzed in a Swedish Population. JDR 2015, 2016

**Biological Complications**

Early failures  
Inflammation:  
- Peri implant mucositis  
- Peri implantitis  
Recession

**Technical Complications**


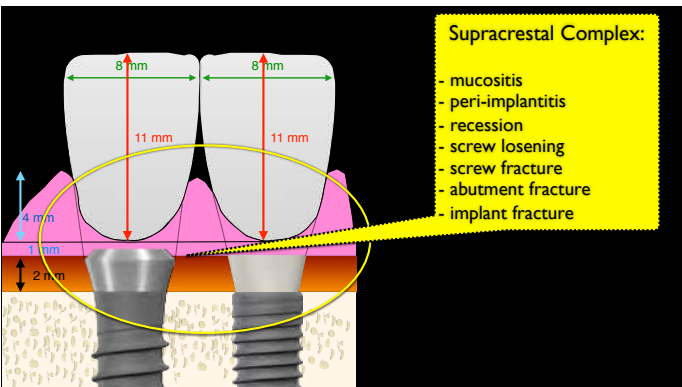
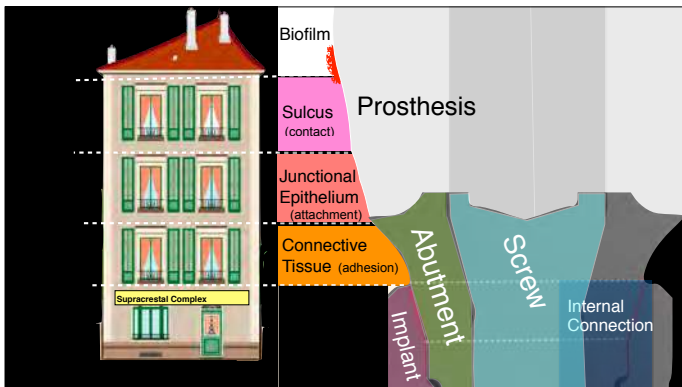
Veneer chipping / fracture  
Framework fracture  
Screw loosening  
Screw fracture  
Abutment fracture  
Loss of retention  
Implant fracture



The impact of cantilevers on biological and technical success outcomes of implant-supported Fixed Partial Dentures.  
 P. Kim, S. Ivanovski, N. Latcham, N. Mattheos.  
 COIR 2012

206 patients, 272 FPDs, 50 months

- Complications are clustered
- technical complications were 3 times more likely to be associated with biological complications


...to do list

**Patient**

1. Host and Behavioral factors
2. Systemic Risk
3. Ability for Oral Hygiene

**Prosthesis**


4. Evaluate Prosthesis and its design
5. Assess Condition of all Components



...to do list


**Prosthesis**

- Abutment fit
- Abutment screw (fracture / unscrew)
- Framework fit
- Veneering ( chipping / cracks
- Cement excess
- Implant shoulder (fracture )





**...to do list**



**Patient**


1. Host and Behavioral factors
2. Systemic Risk
3. Oral Hygiene

**Prosthesis**

4. Evaluate Prosthesis and its design
5. Assess Condition of all Components
6. Assess accessibility to Oral Hygiene

**Soft and hard Tissues**

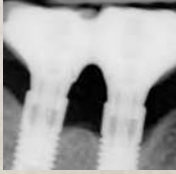
7. Probing depths
8. Bleeding on Probing
9. Recession
10. Bone level



**ASSESS THE PROSTHESIS**

**Maintenance**


- Is effective oral hygiene possible?
- Is the prosthesis and all components in good condition?




**ASSESS THE TISSUES**

**Maintenance**

- Redness - swelling
- Deposits plaque / stain / calculus
- Recession - Mucogingival problems
- Increased probing depth
- Marginal (or other) bone loss

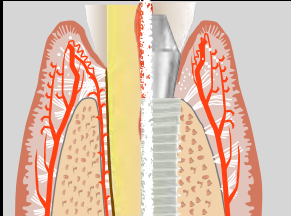


**Dental Implant Id card**

Implant	Straumann SP RN 4.1 x 10mm LOT AC245, REF 021.441Z	Probing Pocket Depth 13/7/2011			
Restoration	Cement Retained PFM Crown	M	D	B	L
Restoration date	12/2/2013	2	2	1	2
Clinician	Dr. N. Mattheos				
Dental Lab	PPDH, Sai Ying Pun				
Contact	clinic@mattheos.net				

Prince Philip Dental Hospital  
Implant Dentistry  
34 Hospital Road  
Hong Kong  
tel. +852 28590 411


<p><b>Periodontal</b></p> <ul style="list-style-type: none"> <li>Physiological</li> <li>Stable in health</li> <li>Contain disease progression</li> </ul>	<p><b>Peri-implant</b></p> <ul style="list-style-type: none"> <li>Repair tissue</li> <li>Stable in health</li> <li>Compromised at disease</li> </ul>
--	--




Implant Dentistry @ HKU


Understanding Implant Complications: **Checkpoint!**

- Complications are part of the picture - be prepared!
- There is an interrelation between technical and biological complications
- A deep understanding of the biological basis and limitations of the technology is the prerequisite for successful practice






Implant Dentistry MOOC @ HKU



THE WORLD'S FIRST  
IMPLANT DENTISTRY MOOC  
BY THE UNIVERSITY OF HONG KONG

ENROL NOW AT :  
[HTTPS://WWW.COURSERA.ORG/LEARN/IMPLANT-DENTISTRY](https://www.coursera.org/learn/implant-dentistry)




Scan me



YouTube [www.youtube.com/c/NikosMattheos](http://www.youtube.com/c/NikosMattheos)



Implant Dentistry Online [www.mattheos.net](http://www.mattheos.net)

HOME ABOUT ME IMPLANT DENTISTRY TEACHING AND LEARNING RESOURCES FEEDBACK



Who's afraid of the deep bed Sulcus-7 (part 1)  
10th April 2019

The concept of Biologic Width has been revised and updated in relation to the deep bed sulcus...  
<https://www.mattheos.net/2019/04/10/whos-afraid-of-the-deep-bed-sulcus-7-part-1/>



Immediate Implants in the Aesthetic Zone?  
10th January 2018

<https://www.mattheos.net/2018/01/10/immediate-implants-in-the-aesthetic-zone/>

[www.mattheos.net](http://www.mattheos.net)




Thank you !!!

[nikos@mattheos.net](mailto:nikos@mattheos.net)  
[www.mattheos.net](http://www.mattheos.net)